

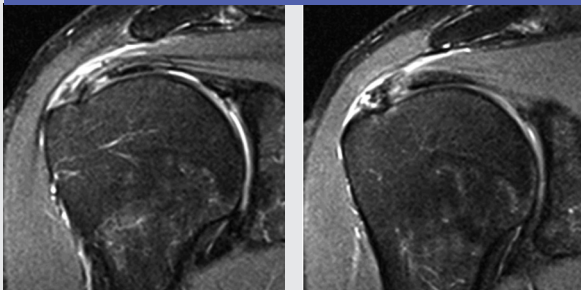
Case Study: Calcific Tendinitis & Partial RTC Tear

+ PATIENT: 42 year-old male drummer
6 months right shoulder pain
MRI: Supra/Infraspinatus calcific tendinitis
Tendon degeneration/partial tears

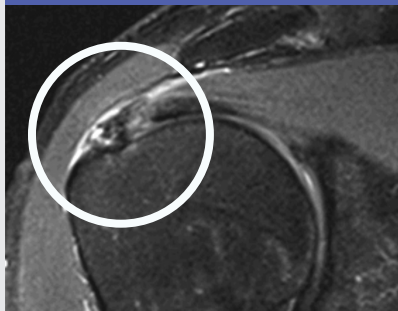
RECALCITRANT TO: Anti-inflammatory meds
PT, acupuncture, chiropractic care
PRIOR TREATMENT: 2 Leverage/Aspirations
Month 1, Month 3. Reduced Pain by 25%

AMNIOFIX® TREATMENT: AmnioFix® Injectable (40 mg)
(1) Ultrasound guided injection Month 8
RESULTS: Soft tissue healing and reduced symptoms
by >90%

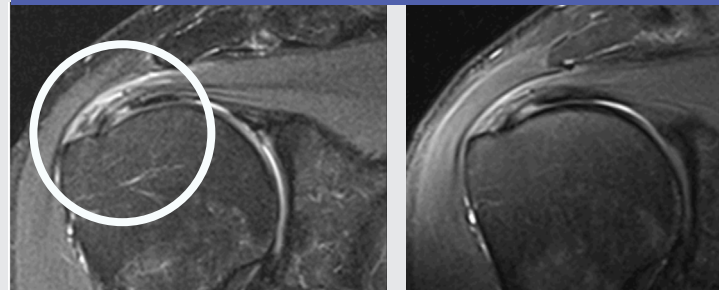
MONTH 1 FIRST LEVAGE/ASPIRATION



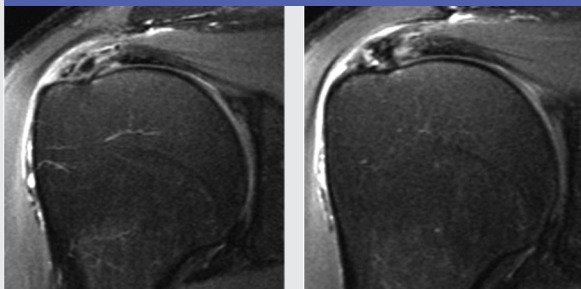
MONTH 8 AMNIOFIX® INJECTION



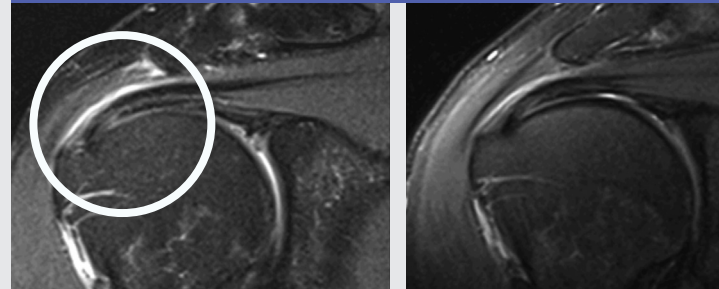
MONTH 10 FIRST FOLLOW-UP MRI



MONTH 3 SECOND LEVAGE/ASPIRATION

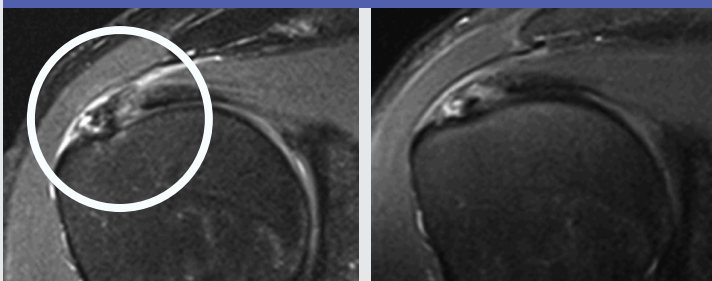


MONTH 12 SECOND FOLLOW-UP MRI

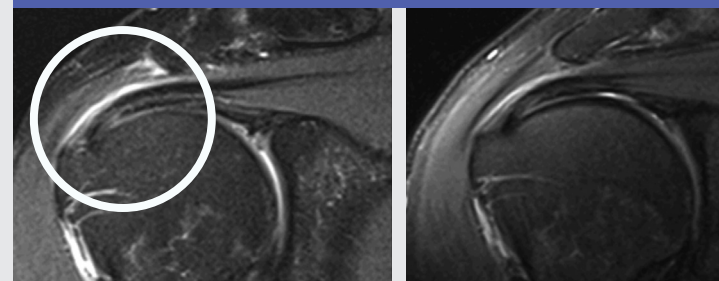


PROGRESSION
OF HEALING
OVER 4 MONTHS

MONTH 8



MONTH 12



Photos Courtesy of Rahul Desai, MD; RestorePDX Sports & Spine, Portland, OR